

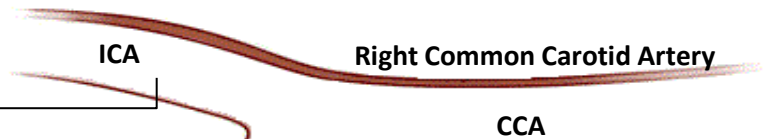


Carotid Duplex Report

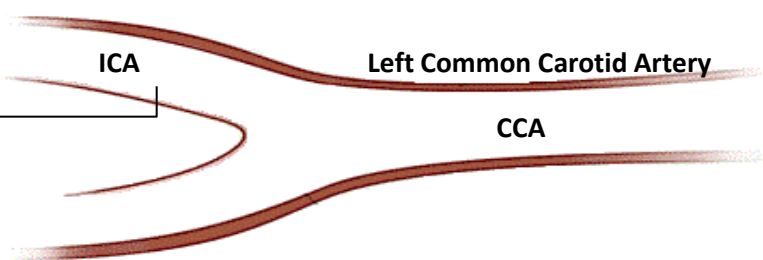
Patient Name: MURRELL, JANICE
DOB: 18-Jul-53

Physician: RASOTGI
Exam Date: 3-Aug-23

Right	ICA	CCA
*PSV:	47	55
*EDV:	13	14
RICA STENOSIS:	20 - 49%	



Left	ICA	CCA
*PSV:	47	48
*EDV:	12	14
LICA STENOSIS:	< 20%	



Left Vertebral Artery
Velocity: 32
Direction: Antegrade

Right Vertebral Artery
Velocity: 40
Direction: Antegrade

Vertebral Artery



COMMENT: Dynamic ultrasound scanning of the neck was performed with carotid duplex (Doppler & B-Mode ultrasound) arterial analysis including color flow and spectral analysis; Abnormal bilateral carotid duplex ultrasound exam. Significant plaque found in LEFT Carotid Artery; Moderate plaque found in RIGHT Carotid Artery; Unable to obtain right vertebral artery images due to patient body habitus. Screening Carotid Doppler indicates hemodynamically significant stenosis within the left carotid system. Suggest full Carotid Doppler examination to further evaluate for severity of stenosis.

Physicians Signature: _____



